

*This patient was referred by an ENTA physician. Our shared EHR facilitates a seamless referral process and transfer of medical records with the push of a button.*

## **Glomus Jugulotympanicum Tumors**

**A 73-year-old woman with pulsatile tinnitus and conductive hearing loss was diagnosed with a glomus jugulotympanicum tumor.**

### **Clinical Signs and Management:**

The Garden City ENT and Allergy Associates patient presented to the Ear Institute at New York Eye and Ear Infirmary of Mount Sinai after experiencing left pulsatile tinnitus and slight/mild conductive hearing loss for several months. A red glomus tympanicum could be seen pulsating medial to the tympanic membrane. CT scan showed a well-defined mass emanating from the cochlear promontory.

The patient was taken to the operating room and the mass was removed using a transcanal endoscopic approach. Surgeons were able to achieve gross total resection as well as preserve all middle ear structures. After the operation, the patient's pulsatile tinnitus and hearing loss were resolved, and she was extremely pleased with the results.

Glomus jugulotympanicum tumors are best treated in high volume, specialized centers such as the Ear Institute at New York Eye and Ear Infirmary of Mount Sinai, particularly those offering the endoscopic approach for resection. Mount Sinai faculty have published extensively on planned subtotal resections, particularly in younger jugulare patients with advanced tumors and functional lower cranial nerves. A wait-and-scan approach is reasonable for those without malignancy or brainstem compression.

### **Clinical Review**

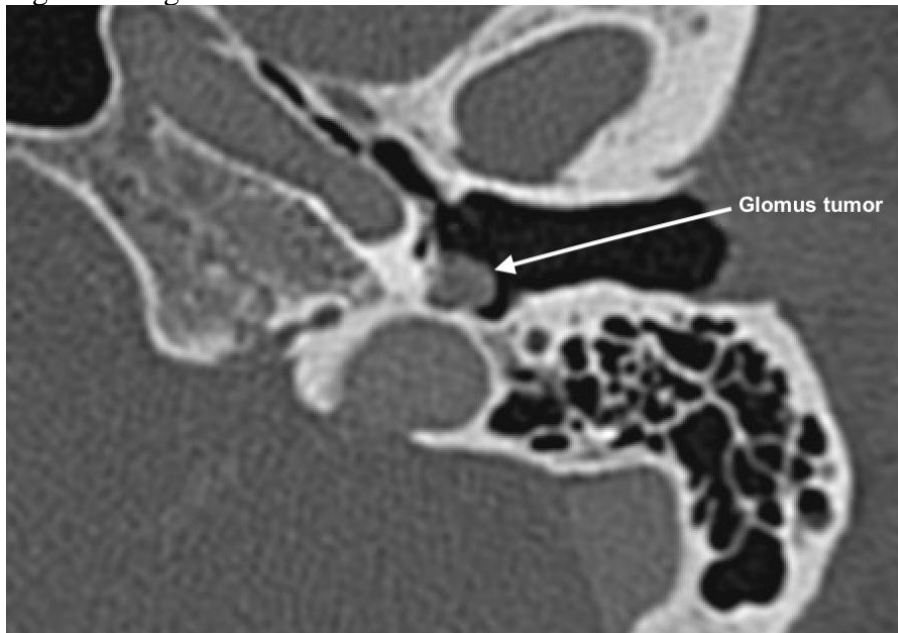
Glomus tumors are rare tumors of the neural crest and include glomus tympanicum, jugulare, vagale, and carotid body tumors. They are more common in women and rarely secretory in the head and neck. Less than half of glomus tumors are inherited, and genetic testing may reveal characteristic mutations (VHL, SDHA-D, VEGF, RET, etc) with varying prognostic value. Most

frequently, pulsatile tinnitus and conductive hearing loss will be presenting symptoms of jugulotympanic tumors.

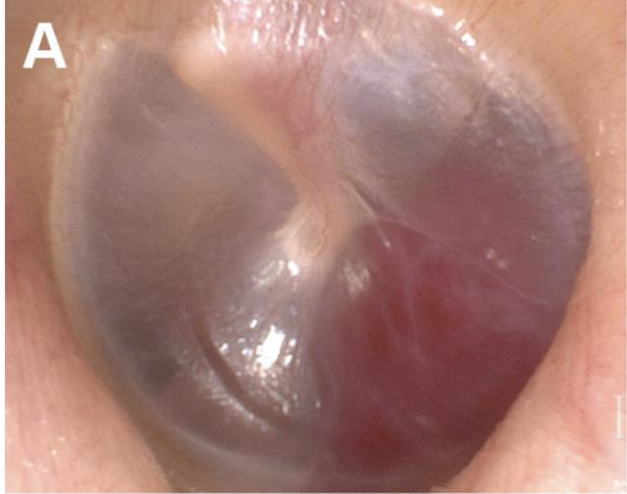In more advanced cases, a jugular foramen/hypoglossal canal syndrome may develop, affecting nerves IX-XII with resultant dysphagia, vocal cord immobility, shoulder weakness, and tongue wasting/atrophy. Facial weakness is uncommon but may occur. CT will show a well-encapsulated mass on the promontory for tympanicum tumors, while a jugulare tumor will erode the caroticojugular spine and may extend into the middle ear or invade intra/extradurally.

Diagnostic biopsy prior to definitive treatment is generally not advocated due to the brisk bleeding that may occur. Lesions will avidly enhance on MRI and must be delineated from schwannomas, meningiomas, metastases, and endolymphatic sac tumors. Gallium-68 DOTATATE scans may help confirm the diagnosis in equivocal cases. While locally destructive, these tumors do not usually metastasize.

Figures w legends:



Axial Compute tomography non-contrast scan showing glomus tympanicum tumor on the cochlear promontory.



Transcanal endoscopic view of representative left glomus tympanicum medial to the tympanic membrane from Sweeney AD, Carlson ML, Wanna GB, Bennett ML. Glomus tympanicum tumors. Otolaryngol Clin North Am 2015;48:293-304.



George Wanna, MD  
Professor of Otolaryngology and Neurosurgery  
Chair of the Department of Otolaryngology  
Mount Sinai Downtown (New York Eye and Ear Infirmary and Mount Sinai Union Square)  
Chief of Otology-Neurotology  
Mount Sinai Health System



Zachary Schwam, MD  
Neurotology Fellow